

Case Report

Zimmermann-Laband Syndrome in a Six-year-old Girl: A Case Report

Masoumeh Khoshhal¹ • Hengameh Khosropanah² • Fariborz Vafae^{3*} • Mahdi Kadkhodazadeh¹ • Janet Moradi Haghighi¹ • Parviz Torkzaban¹ • Ashkan Mahmoodi²

¹Assistant Professor, Department of Periodontology, Faculty of Dentistry, Shiraz University of Medical Sciences, Shiraz, Iran

²Assistant Professor, Department of Periodontology, Faculty of Dentistry, Hamadan University of Medical Sciences, Hamadan, Iran

³Associate Professor, Department of Prosthodontics, Faculty of Dentistry, Hamadan University of Medical Sciences, Hamadan, Iran

*Corresponding Author; E-mail: fvafae@gmail.com

Received: 6 April 2010; Accepted: 31 May 2010

J Periodontol Implant Dent 2010; 2(1): 43-46

This article is available from: <http://dentistry.tbzmed.ac.ir/jpid>

© 2010 The Authors; Tabriz University of Medical Sciences

This is an Open Access article distributed under the terms of the Creative Commons Attribution License (<http://creativecommons.org/licenses/by/3.0>), which permits unrestricted use, distribution, and reproduction in any medium, provided the original work is properly cited.

Abstract

Zimmermann-Laband syndrome is an inherited disease characterized by extensive gingival enlargement and abnormalities of the head, face, hands, feet, nose, and ears. Hypoplastic or absent nails, mild hair loss, and mental retardation are seen in some cases. The present paper describes a patient, aged six and half years, with typical features of Zimmermann-Laband syndrome.

Key words: abnormality, gingiva, malformed nails.

Introduction

Increase in the number of the cells of the gingival is referred to as overgrowth or enlargement. Another histological term in this regard is hyperplasia, which is an increase in the size of the cells. The causes of gingival overgrowth in children has been known to include drug-induced gingival overgrowth, hereditary gingival fibromatosis, neurofibromatosis I, leukemic gingival infiltrates, gingival hyperplasia as a manifestation of Hodgkin's lymphoma, sweet-like syndrome and Schinzel-Giedion syndrome.¹

Zimmermann-Laband syndrome, listed under the category of hereditary gingival fibromatosis, is a very rare status characterized by a generalized enlargement of facial and lingual surfaces of the attached and marginal gingiva, abnormalities of nose or ears, hypoplastic or absent nails and mild hair loss.²⁻⁴ It was origi-

nally described in 1928 by Zimmermann,⁵ and later again in 1940 by Jacoby et al.⁶ In 1964, Laband et al⁷ reported another case of this syndrome. The present paper describes a child patient with typical features of Zimmermann-Laband syndrome.

Case Report

A six-and-a-half-year-old girl was referred to the Department of Periodontology at Hamadan University of Medical Sciences for an examination of her gingival enlargement. The chief complaint was the unesthetic appearance and excessive gingival overgrowth in the anterior region of the mouth, which almost covered all deciduous teeth (Figure 1).

Intra-oral examination showed an extensive pale-pink firm enlargement of gingiva involving the maxillary and the mandibular arches, prominent maxilla, anterior open bit and mouth breathing. Marginal gingi-

vitis was seen in the regions with semi-erupted teeth. The gingival enlargement also had involved the palate of maxilla and affected the patient's speech.

Full-mouth radiographs taken with long-cone paralleling technique showed presence of all deciduous teeth and tooth buds of permanent teeth (Figure 2).

Extra-oral examination revealed sparse hair, thick ears and lips, bulbous soft nose, thick eyelashes and eyebrows, mild hirsutism in her arms and legs, hypertelorism, telecanthus, high foot arch, and malformed nails with the missing of nail on first finger of the left hand, and second and third fingers of both feet (Figure 3).

A search in the hospital records indicated that the patient was born after a full-term uncomplicated pregnancy. The patient's weight at birth was 3.25 Kg. The child's parents were cousins; her mother was 26 and father 31 years old when the child was born. The patient was their first and only child.

The patient's medical history demonstrated ventricular septal defects with moderate risk associated with infective endocarditic, and no history of medication. Zimmermann-Laband syndrome was included in the differential diagnoses, and as the mental retardation has been reported in some cases of this syndrome, the

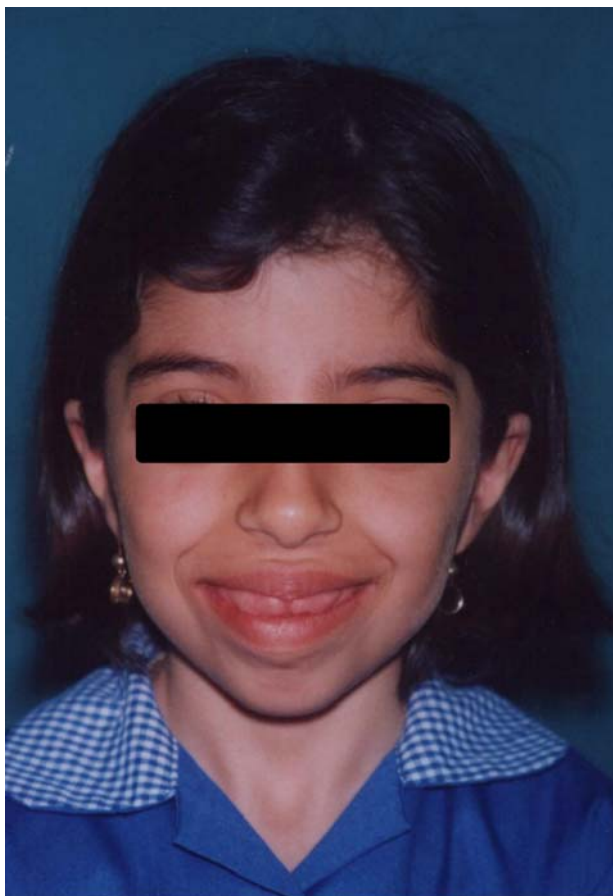

Figure 1. Facial view.

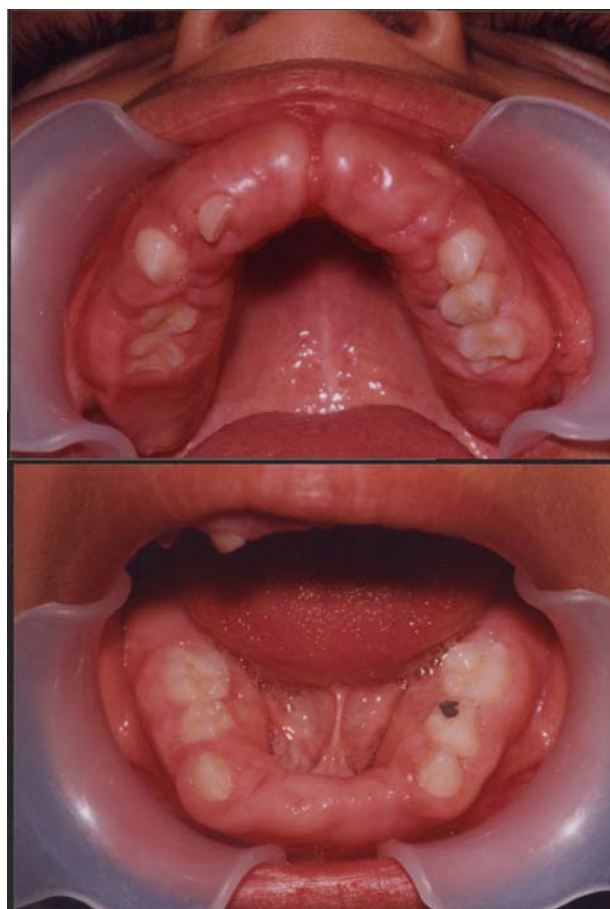

Figure 2. Massive gingival hyperplasia covering all the maxillary and mandibular teeth. Note the pale pink.

patient was referred for an intelligence quotient (IQ) test. The patient's IQ score was in the normal range. This syndrome should be differentiated from other condition with gingival enlargement in children like, drug induced, hereditary and systemic related gingival enlargement. The diagnosis of this case was based on patient history, clinical finding, systemic evaluation, and consultation with a pediatric specialist.

The treatment procedures included plaque removal, plaque control and patient education to treat the marginal gingivitis, and gingivectomy to facilitate the eruption of teeth and improve the esthetics. Reverse bevel gingivectomy was performed under local anesthesia quadrant by quadrant with an interval of approximately 4 weeks between surgeries (Figure 4). Because of the ventricular septal defect in the patient, antibiotic prophylactic regimen was prescribed as 1 g Amoxicillin one hour before the surgery. A 0.2% chlorhexidine gluconate mouthwash was ordered to be rinsed twice a day for 2 weeks post-surgically. The histopathology results from the gingivectomy biopsy showed an increase in the number of fibroblasts, collagen bundles, and the amount of connective tissue, and

a few inflammatory cells. The results of gingivectomy were better esthetic appearance and speech as well as

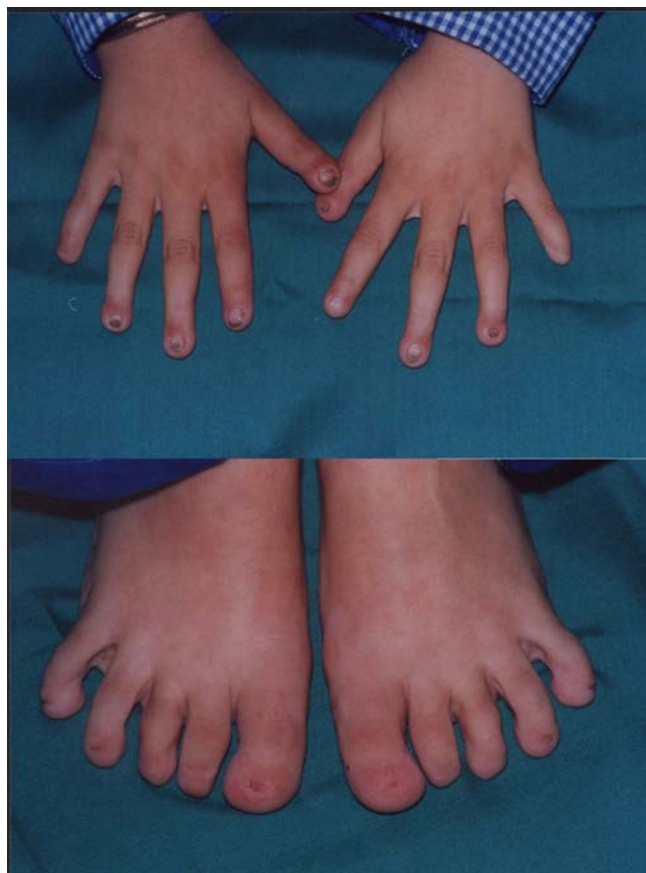


Figure 3. Striking malformation of the hands and feet were found. The patient had malformed nails; the first finger of the left hand as well as the second and the third fingers on both feet had no nails.

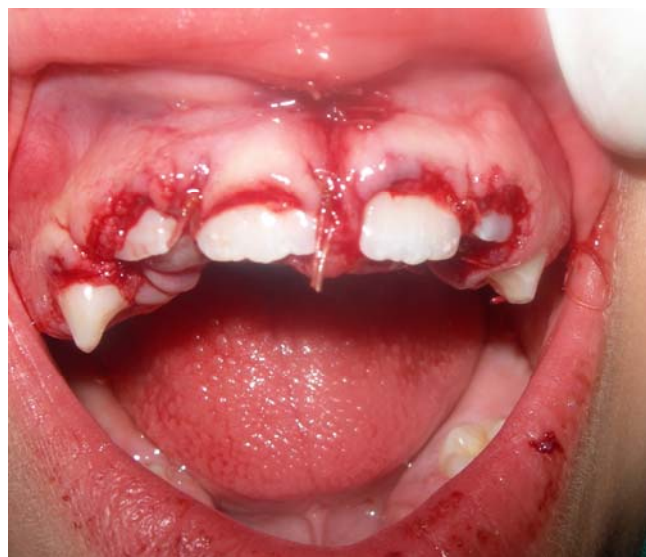

Figure 4. Gingivectomy.

facilitating the eruption of the teeth.

Discussion

The pathogenesis of Zimmermann-Laband syndrome is unknown; however, Alavandar⁸ reported this syndrome with an autosomal dominant trait. The genetic location associated with this syndrome has recently been found on 2p21-p22 (HGF1), 5q13-q22 (HGF2),⁹ and the SOS1 gene.¹⁰

In order to diagnose this syndrome, a detailed medical history and physical examination is necessary, which help differentiate gingival fibromatosis from other types of hereditary or acquired generalized gingival enlargements. The radiographic examination is an adjunct to the clinical examination. Although gingival fibromatosis is a benign condition, impairment of normal eruption in the permanent dentition, esthetics, and function can be convincing reasons for surgical intervention in order to reduce the excessive gingival tissue. Other clinical features observed in some case with this syndrome is hyper extensibility of joint, spina bifida, large tongue, partial anodontia, learning disability, tremor, retinitis pigmentosa, epilepsy, cataract.² Our case did not have these features.

Microscopic findings are not pathognomonic because they cannot be used to differentiate this syndrome with other types of hereditary gingival enlargement. In summary this syndrome is not a killer disease but needs a good diagnosis, treatment, follow-up and oral hygiene control.

References

1. Doufexi A, Mina M, Ioannidou E. Gingival overgrowth in children: epidemiology, pathogenesis, and complications. A literature review. *J Periodontol* 2005; 76:3-10.
2. Shah N, Gupta YK, Ghose S. Zimmermann-Laband syndrome with bilateral developmental cataract - a new association? *Int J Paediatr Dent* 2004; 14:78-85.
3. Douzgon S, Mingarelli R, Dallapiccola B. Gingival overgrowth, congenital generalized hypertrichosis, mental retardation and epilepsy: case report and overview. *Clin Dysmorphol* 2009; 18:205-8.
4. Kissi L, Benyahya I, Rifki A. [Syndromic gingival fibromatosis]. *Rev Stomatol Chir Maxillofac* 2006; 107:477-80. French.
5. Zimmermann L. Über anomalien des ektoderms. *Vjschr Zahnheilkd* 1928; 44:419-434. German.
6. Jacoby NM, Ripman HA, Munden JM. Partial anonychia (recessive) with hypertrophy of the gums and multiple abnormalities of the osseous system: report of a case. *Guys Hospital Report* 1940; 90:34-40.
7. Laband PF, Habib G, Humphreys GS. Hereditary gingival fibromatosis. Report of an affected family with associated splenomegaly and skeletal and soft-tissue abnormalities. *Oral Surg Oral Med Oral Pathol* 1964; 17:339-51.
8. Alavandar G. Elephantiasis gingiva: report of an affected family with associated hepatomegaly, soft tissue and skeletal abnormalities. *J Indian Dental Assoc* 1965; 37:349-53.

9. Hart TC, Pallos D, Bozzo L, Almeida OP, Marazita ML, O'Connell JR, et al. Evidence of genetic heterogeneity for hereditary gingival fibromatosis. *J Dent Res* 2000; 79:1758-64.
10. Hart TC, Zhang Y, Gorry MC, Hart PS, Cooper M, Marazita ML, et al. A mutation in the SOS1 gene causes hereditary gingival fibromatosis type 1. *Am J Hum Genet* 2002; 70:943-54.